



Intraoperative tissue expansion as an alternative approach for hand syndactyly management to avoid skin grafts in children

Intraoperativna tkivna ekspanzija kao alternativni pristup u rešavanju sindaktilija šake kod dece bez primene kožnih transplantata

Djordje Kravljanac*, Radoje Simić*†, Ivan Milović*†

Institut for Mother and Child Healthcare of Serbia “Dr Vukan Čupić”, *Department of Plastic Surgery and Burns, Belgrade, Serbia; University of Belgrade, †Faculty of Medicine, Belgrade, Serbia

Abstract

Background/Aim. A great number of syndactyly release techniques have been described over last two centuries. The aim of our study is outcome assessment of congenital syndactyly surgery using temporary tissue expansion of the dorsal hand and local flaps, without skin grafts. **Methods.** This study included children with congenital hand syndactyly treated in period from 2009–2015 by operative technique with temporary tissue expansion of the dorsal hand skin and local flaps, without skin grafting. In all cases surgery was performed under general anesthesia. According to Weber’s descriptive method, the functional outcome at the end of the follow-up period was categorized as good, fair or bad. All patients were evaluated for associated anomalies. **Results.** A total of 26 children (20 males, 6 females), aged from 6 months to 6 years (average age of 23 months), were operated by previously described technique. There were 20 patients with complete syndactyly and 6 with incomplete, mostly involving the third web. Associated anomalies were diagnosed in 9 patients. The follow-up period ranged from 1 to 5 years with average duration of 2.6 years. The functional results were good in 20 patients, fair in 5 and bad in 1 patient. **Conclusion.** Surgical procedure with temporary tissue expansion of the dorsal hand skin and local flaps, without skin grafting is effective method of congenital syndactyly treatment in children with good functional and aesthetic results. The advantages of this technique are the reduction of surgery duration and avoiding certain complications, such as web hair growth, hyperpigmentation and hypertrophic scars.

Key words:

congenital abnormalities; polydactyly; reconstructive surgical procedures; infant; child, preschool; treatment outcome.

Apstrakt

Uvod/Cilj. U rešavanju sindaktilije šake kod dece u proteklih 200 godina primenjivan je veliki broj hirurških tehnika. Cilj rada je bila procena ishoda lečenja kongenitalne sindaktilije šake primenom tehnike privremene tkivne ekspanzije i lokalnih režnjeva bez upotrebe kožnih transplantata. **Metode.** Studijom su obuhvaćena deca sa urođenom sindaktilijom šake koja su u periodu 2009–2015. operativno lečena primenom tehnike privremene ekspanzije kože sa dorzalne strane šake i lokalnih režnjeva bez upotrebe kožnih transplantata. Sve operacije su urađene u opštoj anesteziji. Funkcionalni ishod lečenja određivan je prema Weberovoj deskriptivnoj metodi kao dobar, zadovoljavajući i loš. Svi bolesnici su ispitivani radi dijagnostikovanja udruženih anomalija. **Rezultati.** Ukupno 26 dece (20 dečaka i 6 devojčica), uzrasta od šest meseci do šest godina (srednji uzrast 23 meseca), operisano je opisanom tehnikom. Dvadeset bolesnika imalo je potpunu, a šest nepotpunu sindaktiliju šake. Najčešće su bili zahvaćeni treći i četvrti prst. Udružne anomalije su otkrivene kod devet bolesnika. Period praćenja trajao je od jedne do pet godina, u proseku 2,6 godina. Funkcionalni ishod lečenja bio je dobar kod 20 bolesnika, zadovoljavajući kod pet i loš kod jednog deteta. **Zaključak.** Hirurška tehnika privremene ekspanzije kože dorzalne strane šake sa lokalnim režnjevima bez upotrebe kožnih transplantata predstavlja efikasnu metodu za rešavanje urođene sindaktilije šake, sa dobrim funkcionalnim i estetskim rezultatima. Prednost ove tehnike su vremenski kraća operacija i izbegavanje komplikacija kao što su pojava maljavosti, hiperpigmentacije kože i hipertrofičnih ožiljaka.

Ključne reči:

anomalije; polidaktilija; hirurgija, rekonstruktivna, procedure; odojče; deca, predškolska; lečenje, ishod.

Introduction

Congenital hand differences may significantly affect human's professional abilities and social lives. Syndactyly is one of the most common congenital anomaly of the hand in children. It occurs with an incidence of one in every 2,000 births¹. Fingers are webbed, they create functional limitations and an abnormal appearance. In most cases, it presents an isolated malformation, while less frequently it is combined with other congenital abnormalities, such as typical cleft hand or as a part of a syndrome (Apert's and Poland's syndrome). Syndactyly is classified as complete if it extends up to the tip of the involved fingers, or incomplete if the involved fingers are partially connected. It is defined as simple if only the skin and the underlying soft tissue of the fingers are fused, or as complex, in the presence of concomitant bone fusion^{1,2}. The treatment goal for syndactyly is to create web space as natural as possible in order to improve the function and appearance of each finger. A great number of syndactyly release techniques have been described over the last two centuries to provide adequate interdigital space and cutaneous coverage for every aspect of the affected digit. The classical teaching has been that skin graft is necessary for covering the dorsolateral surfaces of separated fingers, since the primary closure is not possible. Zigzag incisions along the full length of the fused digits are used to create interdigitating flaps for wound closure since the separation of the digits by longitudinal incisions will invariably cause scar contractures. Kozin³ reported that the skin grafts have a tendency to contract and lead to finger flexion contractures and "creep" of the web space. We have developed a surgical technique with temporary intraoperative skin expansion that does not require skin grafts. With this technique, we have reduced the surgery time and the possibility of hypertrophic scar formation and avoided certain complications such as web hair growth and hyperpigmentation involving skin grafts.

The aim of our study was to present our own results of temporary intraoperative tissue expansion of the dorsal hand side and local flaps without skin grafts in the treatment of congenital hand syndactyly in children.

Methods

Our prospective study included children with congenital hand syndactyly treated in our Institute by operative technique with temporary tissue expansion of the dorsal hand skin and local flaps, without skin grafting in the period from January 2009 to January 2015. The following conditions were excluded to make the study group more uniform: patients older than 10 years of age, children with complicated hand syndactyly (skeletal abnormalities), Apert's syndrome, Poland's syndrome and amniotic band syndrome. In all cases surgery was performed under general anesthesia and the loupe magnification. The collected variables covered data such as: patient age at the time of operation, sex, type and location of syndactyly, the presence of associated congenital anomaly, complications and postoperative outcome. Accord-

ing to Weber's descriptive method, the functional outcome at the end of the follow-up period was categorized as good, fair or bad. The results are considered to be good if all of the following criteria are fulfilled: natural appearance of the commissure, a flat, smooth scar, a good color match between local skin and skin flaps, full flexion and extension of the operated digit when compared to the contralateral side [or no impairment of range of motion (ROM)] and to preoperative findings in complex syndactylies. The results are considered to be fair by the author if there was a slight aesthetic deficit such as hypertrophic scars that did not compromise the full ROM of the separated fingers. The results were poor if the severe hypertrophic scars or keloids were found, or the patient needed to be reoperated⁴. This investigation was approved by the Institutional and the University Ethical Board. Informed consent was obtained by parent of each patient before operative treatment.

Surgical technique

The operation was done under tourniquet control without exsanguinations for better visualization of the neurovascular bundle (Figure 1).

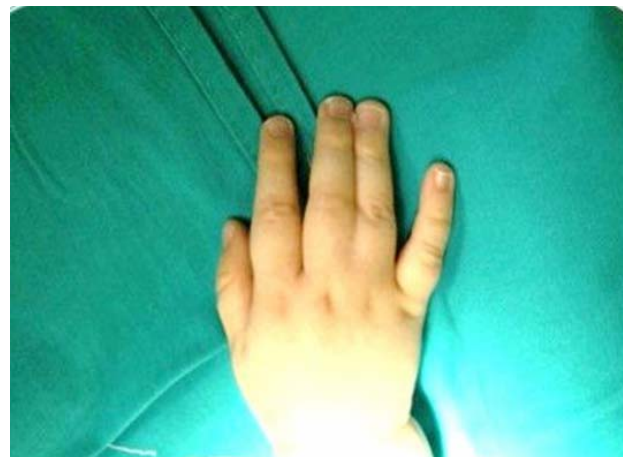

Fig. 1 – Preoperative photograph of the patient with complete syndactyly of the third web space.

Incision markings on the dorsal side of conjoined fingers were made in traditional zigzag fashion to create triangular flaps, with the mirror image incision marked on the palmar side to create interdigitating flaps. Markings for the interdigital commissure on the dorsal side were composed in "sand clock" form modified by D'Arcangelo et al.⁵ (omega flap). The apex of the flap was designed to reach the level of the middle portion of the proximal phalanges. Incisions were marked on the volar side to create an anchor shape with two lateral flaps at the base of the two adjacent fingers (Figure 2). Before starting the procedure Foley silicone catheter was put under the skin through a small incision on the dorsal side of interdigital region of web fingers. The incision to insert catheter balloon expander was made at the line surface between apex of the dorsal skin omega flap and the beginning of the triangular flap for lateral side of the digit. Balloon on the distal end of catheter was insufflated with 5 mL saline and

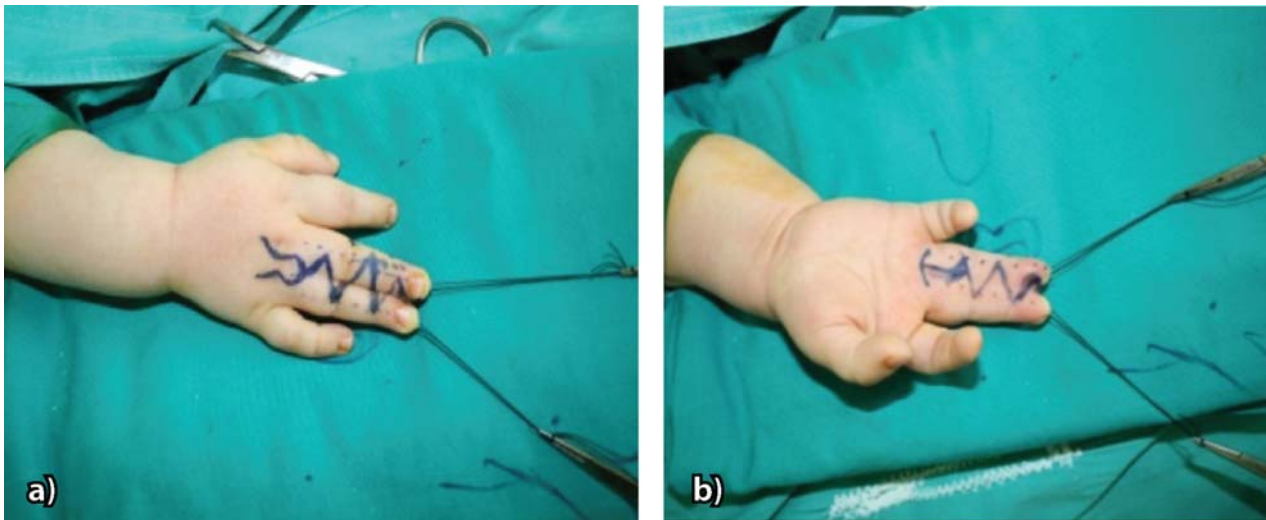

Fig. 2 – Preoperative markings for incisions of the dorsal (a) and volar (b) surface of the conjoined fingers.

expanded the skin (Figure 3). The fingers were separated along the zigzag incisions and 20 min later the temporary skin expansion silicone catheter was moved out. Dorsal full-thickness flap created from the expanded skin was advanced through web spaces and distal tip was sutured to the palmar skin to make commissure (Figure 4). Small areas of the

dorsal proximal parts of the fingers were covered with local flaps created from the expanded skin. The technique did not need skin grafts to constitute the web space. The extra fat was trimmed under magnification avoiding injury to the underlying neurovascular bundles. Triangular flaps were mobilized and sutured using absorbable suturing material in

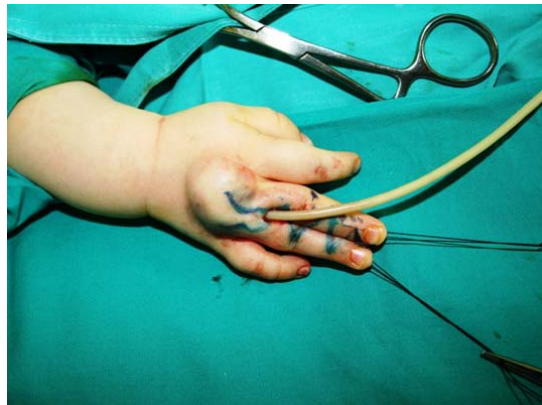

Fig. 3 – Intraoperative temporary tissue expansion of the dorsal hand skin using silicone catheter.

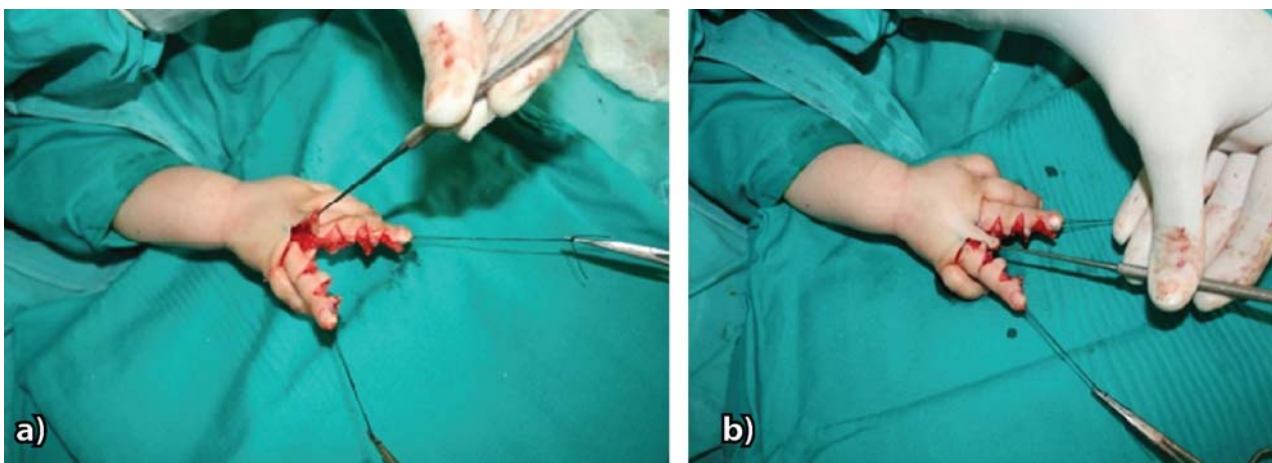


Fig. 4 – The modified omega flap being raised from the dorsum expanded skin of the hand: a) and b). The flap is mobilized and advanced distally and volarly to fill the newly created interdigital commissure.

place to completely primarily close the defects along the sides of the two separated fingers. For complete syndactyly in which the nails are united, laterally based skin flaps from the distal pulp were elevated to create the nail fold as advocated by Buck Gramko⁶. After suturing with absorbable stitches, the tourniquet was released for control of hemostasis and assessing flap circulation (Figure 5). The operated area was dressed using topical antibiotic cream, cotton foam and dry gauze in the web space. A usual hand adhesive dressing was done with tape bandage immobilization.

Results

All reviewed patients in our study were operated by the presenting author. There were 20 (76.9%) males and 6 (23.1%) females out of 26 children operated by described technique over the period studied.

The age at which the first surgery was done ranged from 6 months to 6 years with the median age of 23 months. Totally patients 18 (62.3%) were operated before 24 months

of age and 8 children (37.7%) were treated between 2 and 6 years of age.

In relation to the type of the fingers webbing, 20 (76.9%) patients had complete, while 6 (23.1%) children had incomplete syndactyly. Twenty four of syndactylous webs were simple and 2 were complex in which fingers, except the soft tissue connection, had bones united in the distal part of the distal phalanges.

Considering location of syndactyly, the third web was most commonly involved (13 children). The second web was affected in 8 cases, while the fourth web was involved in 3 patients; 2 children had conjoined middle, ring and small fingers at the same time (Figure 6). The complete functional recovery of one such patient using described operative technique can be viewed in the Figure 7. There were 6 patients with bilateral syndactyly, 7 with right hand involved and in 13 children the left hand was affected.

Associated congenital anomalies were diagnosed in 9 patients including: hand hypoplasia, hand polydactyly, foot syndactyly and obstructive megaureter.

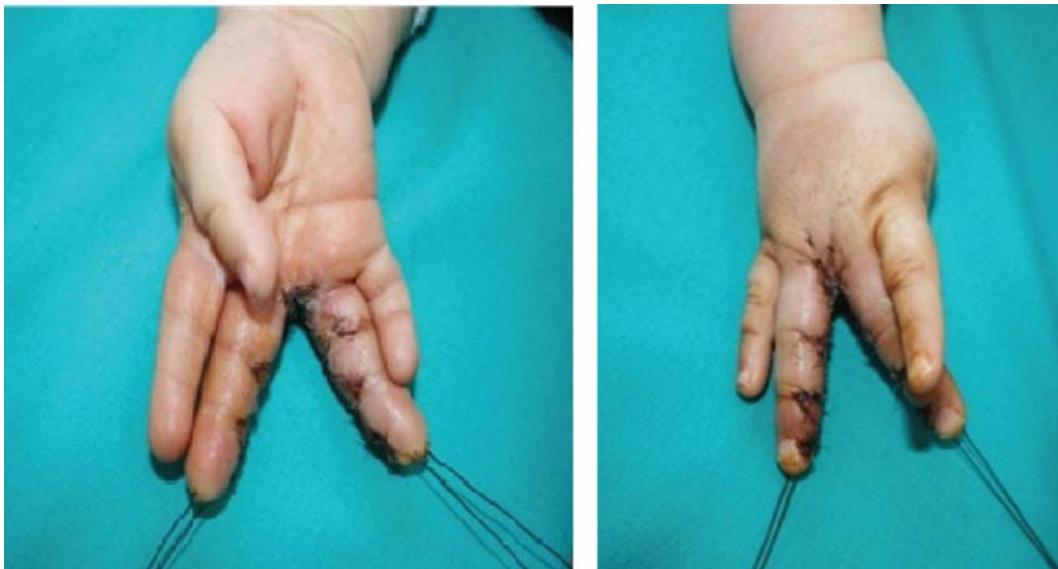


Fig. 5 – Postoperative photographs of the separated fingers.

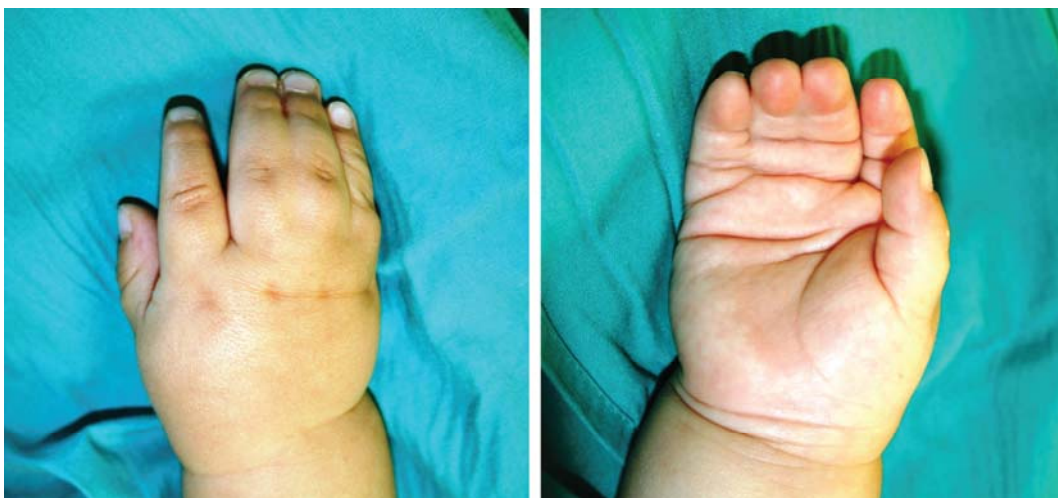

Fig. 6 – Preoperative photographs of a child's hand with conjoined middle, ring and small finger.

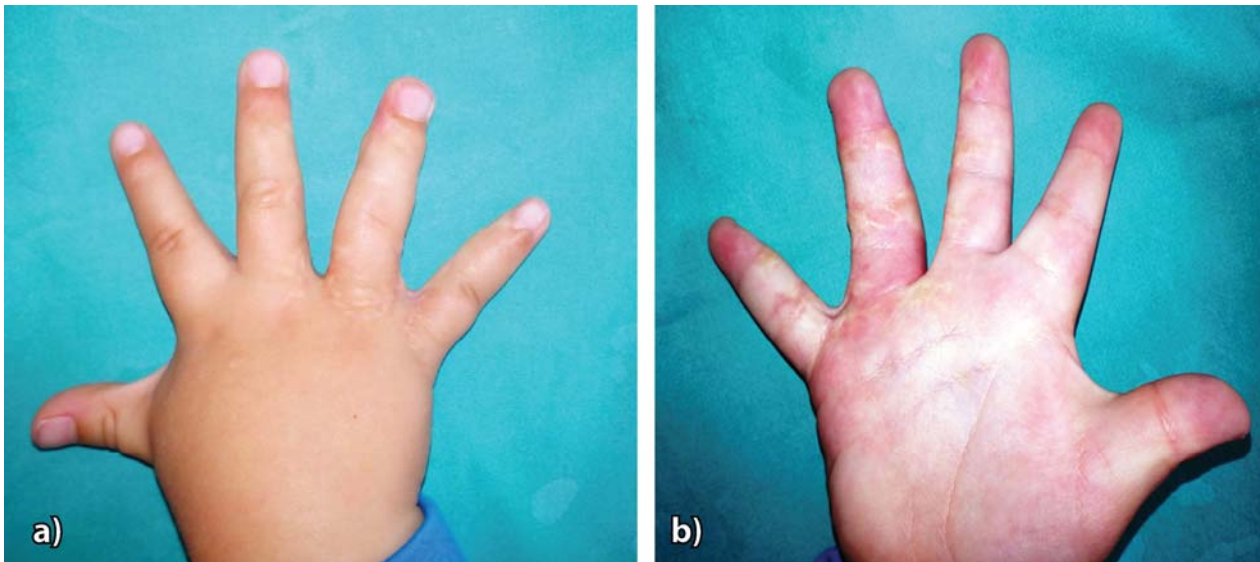


Fig. 7 – Postoperative views of the separated fingers taken at four years of age after three years follow-up of a patient with complete syndactyly of the third and fourth web space at 12 month of age: a) dorsal, b) volar surface of the hand.

All children in our study were treated by described operative technique with dorsal hand skin expansion and local flaps. In all cases we put absorbable sutures (monocril 5.0) to avoid suture removal. The skin grafts were not used for the surgical treatment in any of the patients. We did not have any intraoperative complications.

Considering all the patients together, 24 did not have postoperative complications such as: hematoma, infection, disturbance of the circulation or flap loss. One patient had distal phalanx of index finger deformity, while one had “web creep”.

The follow-up period ranged from 1 to 5 years, with the average period of 2.6 years.

Functional results according to the Weber descriptive method were: good in 20 patients, fair in 5 and bad in 1 case. We achieved a natural appearance and normal shape of the

commissure with smooth scar in more than 76% of the cases. In 96.1% of the patients full ROM was found. Out of the 5 patients with fair results, 4 had slightly hypertrophic scars and 1 had little web creep. One bad case preoperatively had complex and complete syndactyly of the second web with double distal phalanges of the index finger. After separation of the distal phalange digits deformity was developed and the function of the distal interphalangeal joint was compromised. Considering the age when operation was done in the group of patients younger than 24 months of the age, the results were as follows: 15 (83.3%) patients good, two (11.1%) patients fair and one (5.6%) child bad. In the group of the children between 2 and 6 years of the age, the results were as follows: good in 5 (62.5%) patients and fair in 3 (37.5%) cases with no bad results (Figure 8).

Localization and number of interdigital webs

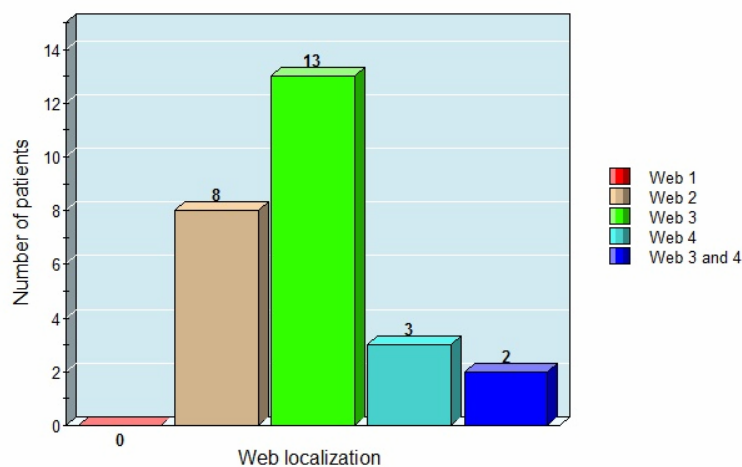


Fig. 8 – Localization and number of interdigital webs.

Discussion

Analyzing surgical results from the operated children with congenital hand syndactyly is always challenging. Among the classification systems for functional evaluations of the hands that exist, none of them is easily applicable to pediatric population.

Among 26 children who underwent syndactyly repair in our study, male patients predominated (76.9%) as it was also found in the literature consulted⁷.

The timing of surgery is controversial in syndactyly release. Hand function was usually established between 6 and 24 months of age. Most surgeons advocate that the operation should be performed before the age of two. They consider that surgical procedure at a later age would be less satisfactory and would have increased complication rate⁸. In our study, good results were observed in 83.3% patients younger than 24 months and 62% children aged from 2 to 6 years. According to our opinion the results are more encouraging if surgery is done at the earlier age because younger children have more elastic skin. The patients mean age at the time of the surgery in our study was 23 months and we agree with the mentioned opinion.

It was reported in relevant literature that most of the patients had incomplete soft tissue syndactyly and that the third web was most commonly involved, as was found in our investigation.

Many techniques of syndactyly release have been described over the last two centuries⁹. Syndactyly surgery include the following three steps: dividing the fingers, commissure reconstruction and resurfacing borders of the separated digits.

Traditional operative procedures for hand syndactyly have used flaps from the dorsum of the web fingers and dorsal and palmar interdigitating flaps. The two separated digits have a greater surface area than a single conjoined digit and most of these techniques employ skin grafts. Historically, split thickness and full thickness skin grafts have both been used to cover remaining surgical defects¹⁰. Deunk et al.¹¹ reported complications associated with skin grafts for syndactyly release. Hands that received skin grafts had a higher incidence of hyperpigmentation, hair growth, scar contracture, web creep and limited spreading of the digits. Review of Moss and Foucher¹² showed 5% to 59% rates of web creep and Percival and Sykes¹³ found 13% of secondary flexion contracture and 15% of web creep in children after skin grafting. Ekerot¹⁴ reported that the use of skin grafts in syndactyly treatment required more time for surgery and more time for complete healing.

For these reasons, surgeons have recently developed several techniques to avoid the use of skin grafts in syndactyly repair. The skin of the normal web is inclined distally in a dorsopalmar direction at almost 40 degrees. The base of the web commissure is normally located at the mid portion of the proximal phalanx. Reconstruction of the new web spaces is the most challenging and the key point in the syndactyly treatment. Niranjani and De Carpentier¹⁵ first described a technique for correction of syndactyly without skin

graft. They used dorsal trilobed flap wider than the currently used flaps and completely covered the interdigital space with no web creep recurrence. Ekerot¹⁴ showed the advantages of non-grafting technique and absorbable skin sutures used in syndactyly release. Several authors recommended V Y dorsal metacarpal advancement flap to create new web space which allows easier primary closure of the proximal phalanges of the separated fingers, without the use of skin grafts^{10, 16}. Extensive defatting of the fingers and the interdigital space has been performed in study of Gruese and Coessens¹⁷. They believed that the removal of fat tissue around the neurovascular pedicle in the interdigital space and along the full length of the fingers allowed for primary closure of the digital flaps without inducing tension. Cetik et al.¹⁸ developed operative procedure with dorsal and volar quadrilateral flaps for the web space that did not require skin grafts. To obtain adequate coverage of the separated digits they used intermittent skin incision on the radial and ulnar side of the fingers in the levels of proximal interphalangeal and distal interphalangeal joint.

Since its introduction by Neumann¹⁹ and refinement by Radovan²⁰ tissue expansion has revolutionized the treatment of skin deficiencies in certain circumstances. Dorsal hand skin near the web space has a good elastic structure and can be easily elongated to the interdigital space. It offers an excellent color, thickness and texture matching the adjacent fingers. Several authors have tested skin expansion of the dorsal hand to increase local tissue available for flap reparation following syndactyly release with various results^{21, 22}. Most of them performed two surgical procedures using small commercial tissue expander to avoid skin graft in syndactyly treatment. Coombs and Mutimer²¹ advocated two operations with skin expansion for reconstruction of the first web in Apert's syndrome hand syndactyly. In the first procedure the authors put tissue expander under the skin and after few weeks following expansion they did second operation consisted of removing the expander and separating the fingers. In some cases, they needed a small skin graft. Two stage skin expansion procedure in Apert's syndrome hand syndactyly was reported with unacceptable rate of complications and higher rate of revision²².

In our study we developed technique of intraoperative temporary skin expansion and local flaps with no grafting surgery to divide conjoined digits in children. Instead of small tissue expander we used Foley silicone catheter with a balloon to expand the dorsal hand skin. With temporary intraoperative expansion lasting 20 min, we got enough skin surface to create adequate flap for new web space and local flaps to cover small proximal phalanges defects of the separated fingers. In that way, we avoided one more operation under general anesthesia and all possible risks. Using Foley silicone catheter with a balloon is a safe method for children and cheaper than traditional skin expander. This is a good solution for conditions when a commercial tissue expander is not available. Dorsal cutaneous flap creates skin of good quality, color and growth into the web compared with skin grafts. We believe as other authors that zigzag incisions along full length of the fingers show lower rate of digital scar

contracture than straight line closure. We agreed with surgeons who recommended defatting of the interdigital space and along the fingers to allow primary closure of the lateral triangular flaps without tension. This maneuver is not easy to perform in young children. The major potential intraoperative complication is injury to the digital artery or nerve while separating and defatting the fingers. This can easily be avoided by carefully identifying and preserving the neurovascular bundle under loupe magnification during dissection. There were also no cases of neurovascular injury of the digits in this series. We recommended using fast absorbable sutures as advocated by Weber and Schiestl⁴ and Ekerot¹⁴. No local side effects were noted and we avoided removal of the suture material which could cause discomfort to the infant. The described technique was used for complete and incomplete hand syndactyly with good results in most of the operated children in our study. It offers adequate soft tissue coverage without skin grafts in all of the cases. The flaps we used have all advantages of a local flap, namely color match, thickness and texture, which make them perfect for web reconstruction. The full range of motion of the digits was not compromised in great majority of the reviewed patients. We have only one bad case with deformity of index distal phalange because the child had double distal phalange of index finger preoperatively. The comparison with other series is difficult because there is no standard assessment score. In our experi-

ence, this surgical procedure for separation of web fingers can be applied easily and safely to pediatric population. This study presents a single center experience with some limitations which have to be corrected in future investigation.

Conclusion

The described technique is an alternative approach for congenital hand syndactyly treatment in children. The advantages of this technique are the reduction of surgery duration and the possibility of hypertrophic scar formation, avoiding certain complications, such as web hair growth and hyperpigmentation involving skin grafts. In addition, there is no donor site morbidity.

Surgical procedure with temporary tissue expansion of the dorsal hand skin and local flaps is an effective method, simple and inexpensive, giving good aesthetic and functional results in most of the patients.

Acknowledgements

The authors would like to kindly acknowledge Dr. Lester Silver, Professor of Plastic Surgery and Pediatrics, Mount Sinai School of Medicine, New York, US for his valuable assistance in critical reviewing and suggestions of the manuscript.

R E F E R E N C E S

1. Kay SP. Syndactyly. In: Green DP, Hotchkiss RM, Pederson WC, Wolf SW, editors. Green's operative hand surgery. 5th ed. Philadelphia: Elsevier Churchill Livingstone; 2005. p. 1381–91.
2. Hutchinson DT, Frenzen SW. Digital syndactyly release. *Tech Hand Up Extrem Surg* 2010; 14(1): 33–7.
3. Kozin SH. Syndactyly. *J Am Soc Surg Hand* 2001; 1: 1–13.
4. Weber DM, Schiestl CM. Absorbable Sutures Help Minimise Patient Discomfort and Reduce Cost in Syndactyly Release. *Eur J Pediatr Surg* 2004; 14(3): 151–4.
5. D'Arcangelo M, Gilbert A, Pirrello R. Correction of syndactyly using a dorsal omega flap and two lateral and volar flaps. A long-term review. *J Hand Surg Br* 1996; 21(3): 320–4.
6. Buck-Gramcko D. Progress in the treatment of congenital malformations of the hand. *World J Surg* 1990; 14(6): 715–24.
7. Niranjan NS, Azad SM, Fleming AN, Liew SH. Long term results of primary syndactyly correction by the trilobed flap technique. *Br J Plast Surg* 2005; 58(1): 14–21.
8. Takashi O, Pushman AG, Chung KC. Treatment of common congenital hand conditions. *Plast Reconstr Surg* 2010; 126(3): 121e–33e.
9. Kraljanc D, Simic R. Tissue expansion technique for treatment of congenital hand syndactyly. *Archdischild* 2014; 99(Suppl 2): A550–1.
10. Yildirim C, Sentürk S, Keklikçi K, Akmaç I. Correction of syndactyly using a dorsal separated V-Y advancement flap and a volar triangular flap in adults. *Ann Plast Surg* 2011; 67(4): 357–63.
11. Deunk J, Nicolai JP, Hamburg SM. Long term results of syndactyly correction: Full-thickness versus split-thickness skin grafts. *J Hand Surg Br* 2003; 28(2): 125–30.
12. Moss AL, Foucher G. Syndactyly: can web creep be avoided?. *J Hand Surg Br* 1990; 15(2): 193–200.
13. Percival NJ, Sykes PJ. Syndactyly: A review of the factors which influence surgical treatment. *J Hand Surg Br* 1989; 14(2): 196–200.
14. Ekerot L. Correction of syndactyly: Advantages with a non-grafting technique and the use of absorbable skin sutures. *Scand J Plast Reconstr Surg Hand Surg* 1999; 33(4): 427–31.
15. Niranjan NS, De Carpentier J. A new technique for the division of syndactyly. *Eur J Plast Surg* 1990; 13: 101–4.
16. Hsu VM, Smartt JM Jr, Chang B. The modified v-y dorsal metacarpal flap for repair of syndactyly without skin graft. *Plast Reconstr Surg* 2010; 125(1): 225–32.
17. Gruese M, Coessens BC. Congenital syndactyly: defatting facilitates closure without skin graft. *J Hand Surg A* 2001; 26(4): 589–94.
18. Cetik O, Ozsar BK, Eksioğlu F, Uslu M, Cetik G. Contrary intermittent skin release of complete syndactyly without skin graft in adults. *Ann Plast Surg* 2005; 55(4): 359–62.
19. Neumann C. The expansion of an area of skin by progressive distention of a subcutaneous balloon; use of the method for securing skin for subtotal reconstruction of the ear. *Plast Reconstr Surg* (1946) 1957; 19(2): 124–30.
20. Radovan C. Tissue expansion in soft-tissue reconstruction. *Plast Reconstr Surg* 1984; 74(4): 482–90.
21. Coombs CJ, Mutimer KL. Tissue expansion for the treatment of complete syndactyly of the first web. *J Hand Surg Am* 1994; 19(6): 968–72.
22. Ashmead D, Smith PJ. Tissue expansion for Apert's syndactyly. *J Hand Surg Br* 1995; 20(3): 327–30.

Received on June 24, 2016.

Revised on July 18, 2016.

Accepted on July 21, 2016.

Online First November, 2016